

IgA Glomerulonephritis*

Mesangial IgA Deposition without Systemic Signs (Berger's Disease)

Judith NAGY, Hilda BRASCH, T. SÜLE, A. HÁMORI, G. DEÁK, Maria AMBRUS

Second Department of Medicine, Department of Pathology, University Medical School,
Pécs, Blood Transfusion Service, Pécs, Hungary

(Received March 6, 1978)

Renal biopsy specimens from 204 patients with glomerulonephritis or nephrotic syndrome have been studied. In ten of the patients not suffering from acute poststreptococcal glomerulonephritis, systemic lupus erythematosus or Schönlein-Henoch syndrome, diffuse, selective mesangial IgA deposition was observed. Clinically, persistent microscopic haematuria, mild proteinuria and, except in one patient, normal renal function were found. Light microscopically the histological picture was dominated by a diffuse or focal increase in volume of the mesangial matrix, and mild mesangial cell proliferation. Exceptionally, there was also crescent formation. Immunofluorescence revealed large IgA, IgG and C3 deposits, as well as small IgM and fibrinogen deposits in the mesangial glomeruli. The authors' assumption that immunocomplexes containing a secretory component might be implicated in the pathomechanism of Berger's disease, could not be proved.

The introduction of immunofluorescence into the histological study of renal biopsy specimens has led, in addition to several etiopathogenetic observations, to the recognition of a new clinico-pathologic entity. The new entity, which is characterized by large amounts of IgA deposited in the glomerular mesangium, was first described by Berger in 1968 [1, 2]. Besides IgA, smaller deposits of IgG and C3 may also be generally observed in similar location. Clinically the new entity is characterized by the absence of systemic sign. In most patients renal function is normal. Microscopic haematuria with a moderate degree of proteinuria is nearly always present. Occasionally, mainly after upper respiratory tract infection, recurrent episodes of gross haematuria have also been reported.

Since Berger's original description, several communications have appeared [2, 3, 5, 6, 8, 10, 15, 18, 19, 20, 21, 23, 26, 27] in which the new clinico-pathological entity is referred to as Berger's disease. The etiology is unknown. The incidence in renal biopsy specimens has been variously put at between 2 and 18 per cent [1, 2, 5, 8, 18, 22, 24, 28].

The present paper describes the clinical symptoms and signs as well as the

* On the basis of a lecture given at the XXIIIrd Itinerary Congress of the Transdanubian Section of the Association of Hungarian Internists, held at Győr on 18th June, 1976.

Supported by the Scientific Research Council, Ministry of Health, Hungary (3-18-0304-03-2/H).

morphological characteristics of the renal biopsy specimens from 10 patients with Berger's disease observed in the past two years, furthermore the results obtained so far in our investigations into the etiopathogenesis of the disease.

Materials and methods

From 204 patients with glomerulonephritis or nephrotic syndrome treated at the Second Department of Medicine, University Medical School, Pécs, in the past two years, adequate amounts of renal tissue for complete histological evaluation were obtained by percutaneous kidney biopsy or at autopsy. In 10 of the 204 patients selective diffuse mesangial IgA deposition was observed. Excluded from the present material are the cases of IgA deposition in which clinically acute post-streptococcal glomerulonephritis, systemic lupus erythematosus (SLE) or Schönlein-Henoch syndrome were found.

In all cases the clinical data of the patients as indicated in this paper refer to the time of the kidney biopsy. For quantitative protein analysis of urine the biuret reaction, and for quantitative determination of haematuria a modification of the Addis method were used [24]. The antinuclear factor (ANF) was demonstrated by indirect immunofluorescence using cryostat sections of native rat liver tissue. Total haemolytic complement activity (CH_{50}) was determined according to Lange [13]; normal values: 1-3 U. The third complement component (C3) was estimated according to Mancini [17]; normal value: 100 ± 22 mg/ml.

Histological studies. The renal biopsy specimens were divided into two parts, for light and immunofluorescence microscopy, and in the case of sufficient material also into a third portion, for electron microscopy.

For *light microscopy* the specimens were embedded in paraffin, according to Saint-Marie [21], cut in 2μ sections, stained with haematoxylin-eosin (HE), periodic acid-Schiff (PAS), periodic acid-methenamine-silver (PEM) and Congo red.

For *immunofluorescence microscopy* another portion of the specimen was immediately frozen in CO_2 . Five μ sections were cut on a cryostat at $-20^\circ C$. The unfixed sections were washed in phosphate buffered saline (PBS) and incubated in a humid chamber at room temperature for 30 min with antiserum labelled with appropriate fluorescein isothiocyanate (FITC). The unfixed reagent was washed out with PBS, then the sections were mounted with buffered 10% glycerol and examined and photographed with a Fluoval (Zeiss) fluorescence microscope using appropriate excitation filters and absorption barrier filters. The following FITC-labelled antisera were used for staining: anti-IgG, anti-IgA, anti-IgM, anti-IgE, anti-C3, anti-fibrinogen (Hyland, Costa Mesa, California) and anti-IgA-SC (secretory component, DACO, Copenhagen).

Results

The clinical data and laboratory findings of our 10 patients with Berger's disease are summarized in Tables 1 and 2.

Table 1 shows that all patients but one were males, generally under 40 years of age. Their renal function was normal. The clinical picture was characterized by persistent microscopic haematuria. The patient whose urinary sediment was

Table 1
Clinical data and laboratory findings at time of renal biopsy

Case No.	Age, years	Sex	RR, mm Hg	Serum		Proteinuria, g/24 hr	Haematuria, million	Gross haematuria in case history
				creatinine, mg/100 ml	BUN, mg/100 ml			
1	39	M	130/90	1.2	29	0.84	48	—
2	16	M	130/90	0.7	12	0.84	17	—
3	33	M	150/95	1.3	18	0.92	6	+
4	44	M	140/90	1.3	17	—	—	—
5	14	M	105/60	1.0	12	—	70	+
6	37	F	130/90	0.6	13	0.4	2	—
7	30	M	110/70	1.0	13	—	4	+
8	30	M	120/70	1.1	9	—	2	+
9	36	M	120/80	1.0	25	1.0	40	+
10	29	M	120/80	1.2	19	2.3	11	—

Table 2

Results of quantitative determination of total complement activity, C3 and serum immunoglobulins

Case No.	IgG, mg%	IgA, mg%	IgM, mg%	CH ₅₀ , U	C3, mg%
1	1040	376	116	0.9	132
2	1160	320	100	2.0	112
3	1340	416	102	1.4	118
4	N.D.	N.D.	N.D.	1.4	N.D.
5	1200	216	48	1.0	80
6	880	396	132	1.1	110
7	2400	468	200	1.3	98
8	1560	444	120	1.1	80
9	1520	436	122	1.6	112
10	480	208	112	1.6	104

N.D. = not done

negative at the time of the biopsy also had had persistent microscopic haematuria earlier. The case histories of five patients show episodes of gross recurrent haematuria, which in two patients appeared after upper respiratory tract infection, in one after strenuous exercise, and in another following tonsillectomy; the fifth had observed haematuria of a few days' duration after revaccination against smallpox. At the time of examination considerable proteinuria was found in one case but hypertension in none.

Table 2 presents the values of serum immunoglobulins, total complement activity and the third complement component. In most cases the serum IgA was considerably elevated. All serum total complement activity values except one, and all C3 globulin levels were normal.

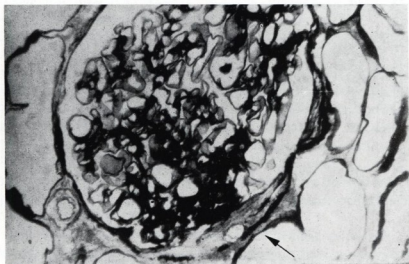


Fig. 1. The mesangial matrix, corresponding to one of the glomerular segments, is increased and a small epithelial crescent (arrow) is seen. PEM, $\times 400$

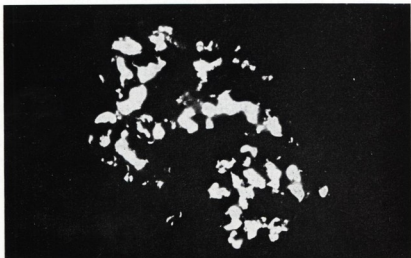


Fig. 2. Large amounts of granular IgA deposition in the glomerular mesangium. $\times 500$

The results of the histological examination of renal biopsy specimens were as follows:

Light microscopy. In each case there was a diffuse or focal increase in mesangial matrix in the glomeruli, which was occasionally associated with mesangial cell proliferation. In one patient the mesangial sclerosis was accompanied by the appear-

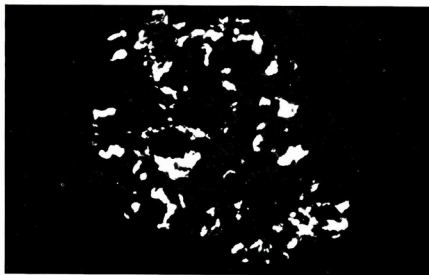


Fig. 3. Large amounts of diffuse granular C3 deposition in the glomerular mesangium. $\times 500$

Table 3
Immunofluorescent findings in renal glomeruli

Case No.	Number of glomeruli examined	Immunofluorescence						
		IgG	IgM	IgA	IgA-SC	IgE	C3	F
1	8	+	±	+++	N.D.	-	++	+
2	10	++	+	++	-	-	+	±
3	10	-	+	++	-	-	++	±
4	7	++	±	++	-	-	++	+
5	18	+	±	++	-	-	±	±
6	8	++	+	+++	-	-	++	+
7	10	++	+	+++	-	±	++	±
8	8	++	±	+++	-	-	++	+
9	8	++	±	+++	-	-	++	+
10	7	++	+	+++	-	-	+	+

- negative; ± traces; + small quantity; ++ moderate quantity; +++ large quantity; F = fibrinogen; N.D. = not done.

ance of small sclerotic epithelial crescents, corresponding to single glomerular segments (Fig. 1). In the biopsy specimens of four patients focal glomerular sclerosis was observed, which generally led to complete destruction of the glomeruli affected.

The results of *immunofluorescence microscopy* are summarized in Table 3. In all cases large mesangial IgA deposits were noted. An illustrative example is given in Fig. 2. In addition, smaller and larger deposits of C3 in similar location were also observed (Fig. 3). In almost every case a minimal amount of IgM, and, except one case, a considerable amount of IgG was also deposited in the glomeruli. Fibrinogen was precipitated in small amounts. IgE positivity in the glomeruli was found in one case, and in two cases also some cells — whose cytoplasm stained positively with anti-IgE — appeared in the peritubular interstitium. In nine cases anti-IgA-SC was used for staining. In no case was an IgA secretory piece seen in the tubular epithelial cells or in the lumina, this observation, however, may be made also in normal kidneys [25].

Discussion

In glomerulonephritides associated with mesangial proliferation, glomerular deposition of IgA immunoglobulins is not rare [1, 5, 8, 10, 14, 18, 19, 24, 28], especially in association with SLE [9], Schönlein-Henoch syndrome [26] and poststreptococcal glomerulonephritis [19, 24]. Berger [1] described a clinical picture easily separable from the above entities, which was histologically characterized by IgA deposited selectively in the glomerular mesangium in the presence of smaller amounts of IgG and C3. The incidence of the disease varies. Berger [1] found it in 18% of all biopsies, while Hyman et al. [8] reported an incidence of 2.1%, Finlayson et al. [5] 2.2%, Zimmermann and Burkholder [28] 3.8%, Sissons et al. [22] 4%, McCoy et al. [18] 4.2%, and Thoenes [24] 9.9%. In our material the incidence was 5%. For designation of the new clinical picture the following terms have been used: Berger's disease, IgA mesangial proliferative glomerulonephritis, IgA-IgG mesangial nephropathy, focal proliferative glomerulonephritis with IgA and recurrent macroscopic haematuria with glomerular IgA.

As shown also by our material, it is chiefly young males that are affected by Berger's disease, which is rarely associated with hypertension. Clinically the most characteristic feature is persistent microscopic haematuria with episodes of recurrent gross haematuria. In addition to the well-known factors provoking gross haematuria (upper respiratory tract infection, strenuous exercise), the characteristic clinical symptom appeared after tonsillectomy in one of our patients and after revaccination against smallpox in another. At the time of the renal biopsy, considerable proteinuria was seen in only one of our patients, in contrast to the observation made by Sissons et al. [22] on patients with marked proteinuria dominating the clinical picture, for whom he set up a special category within Berger's disease.

In the course of serum immunoglobulin studies, we invariably found higher IgA levels, which had been observed earlier also by Lagrue et al. [11, 12] and Zimmermann and Burkholder [28], but has not been confirmed by others [3, 22]. Most authors agree that serum total complement activity and C3 are normal during the disease. As it is shown also by our material, a considerable proportion of the patients have normal renal function; at the same time, however, in 9 out of the 25 patients of Sissons et al. [22] impaired renal function was demonstrated by laboratory examinations.

Light microscopically the mesangial alterations were predominant. Besides diffuse widening of the mesangial matrix, only a moderate degree of cell proliferation was observed, though not in every case. Similarly to Zimmermann and Burkholder [28] and Lagrue et al. [11], we noted several cases of focal glomerular sclerosis, usually accompanied by destruction of the entire glomerulus.

The immunofluorescent picture of the glomeruli of our patients was characterized by selective diffuse mesangial IgA deposition. In addition, however, in every case also smaller amounts of other immunoglobulin fractions appeared in the mesangium. All biopsy specimens except four showed also a considerable degree of mesangial C3 activity.

At first sight the presence of an IgA-bound C3, glomerular in location, seems surprising, because IgA has been demonstrated not to bind complements in the classical way. In 1973, however, Evans et al. [4] observed that IgA also activated complement via the properdin system ("alternative pathway"). This was later confirmed by Sissons et al. [22] and Zimmermann and Burkholder [28], who succeeded in demonstrating properdin in the glomeruli of many patients with IgA nephropathy. According to the investigations by Goetze and Müller-Eberhard [7], aggregated IgA activates complements via the alternative pathway. It is unlikely that the IgG present in variable amounts would be responsible for the C3 deposition, since in our case No. 3 we did not demonstrate IgG in the glomeruli, whereas there were considerable amounts of C3 in them.

The large amounts of IgA invariably present in the serum and kidney tissue may play a primary role in the pathogenesis of Berger's disease. The question, however, is whether or not the disease develops from the circulating immune complexes trapped within the glomerular mesangium. If the mesangial IgA deposition is part of an immunocomplex-mediated process, then there are two alternatives: the IgA in the complex may be present either as an antigen or as an antibody. On the analogy of the glomerular basement membrane, the possibility of auto-antibodies formed against mesangial components also suggests itself. This idea seems to receive support from an observation by Lowance et al. [14], who eluted from the kidney biopsy specimen of one of their patients with Berger's disease a type of immunoglobulin which, when layered over normal human kidney tissue, was bound specifically to the glomerular mesangium. Glomerular IgA deposition may result not only from an immunological process. Certain physico-chemical changes may lead to an aggregation of proteins and the aggregated proteins are incorporated also by the glomerular phagocytic system, the mesangium. This

idea was confirmed experimentally by Mauer et al. [17], who gave aggregated serum proteins to mice intravenously and found that the proteins were deposited preferentially in the glomerular mesangium. Finally it is conceivable, though unlikely, that under pathological conditions the mesangial cells are capable of local IgA synthesis.

Clinical experience has shown that in Berger's disease episodes of macroscopic haematuria may be related to sore throat or to upper respiratory tract infection. In the elimination of infections affecting the mucous membranes an important role is played by the so-called secretory IgA (IgA-SC). We assumed that in such a case immunocomplexes containing IgA-SC as an antibody might circulate and be deposited in the kidneys. Having, however, failed to demonstrate IgA-SC in the glomeruli we could not confirm our assumption. In the same way a negative result was obtained also by Lowance et al. [14], whereas McCoy et al. [18] observed a minimal amount of IgA-SC in the glomerular mesangium in 2 out of 15 patients with Berger's disease.

Nine of our ten patients with renal disease have been under observation for periods varying between one and ten years. During the period of observation there has been no material change in their renal condition. Therefore we also consider Berger's disease to be a type of glomerulonephritis with a relatively good prognosis. Its recognition depends on the immunofluorescent examination of renal biopsy specimens. We regard it as important that it should be differentiated from other glomerulonephritides, first of all from the point of view of prognosis.

References

1. Berger, J.: IgA glomerular deposits in renal disease. *Transplant. Proc.*, 1, 939 (1969).
2. Berger, J., Hinglais, N.: Les dépôts intercapillaires d'IgA-IgG. *J. Urol. Néphrol.* (Paris), 74, 694 (1968).
3. Davies, D. R., Tighe, J. R., Jones, N. F., Brown, G. W.: Recurrent haematuria and mesangial IgA deposition. *J. clin. Path.*, 26, 672 (1973).
4. Evans, D. J., Williams, D. G., Peters, D. K.: Glomerular deposition of properdin in Henoch-Schönlein syndrome and idiopathic focal nephritis. *Brit. Med. J.*, 3, 326 (1973).
5. Finlayson, G., Alexander, R., Juncos, L., Schlein, E., Teague, P., Waldman, R., Cade, R.: Immunglobulin A glomerulonephritis. *Lab. Invest.*, 32, 140 (1975).
6. Germuth, F. G. Jr., Rodriguez, E.: Focal mesangiopathic glomerulonephritis: prevalence and pathogenesis. *Kidney Int.*, 7, 216 (1975).
7. Goetze, O., Müller-Eberhard, H. J.: The C3-activator system: An alternative pathway of complement activation. *J. Exp. Med.*, 134, 90 (1971).
8. Hyman, L. R., Wagnild, J. P., Beirne, G. J., Burkholder, P. M.: Immunglobulin-A distribution in glomerular disease: Analysis of immunofluorescence localisation and pathogenetic significance. *Kidney Int.*, 3, 397 (1973).
9. Koffler, D., Agnello, V., Carr, R. I., Kunkel, H. G.: Variable patterns of immunglobulin and complement deposition in the kidney of patients with systemic lupus erythematosus. *Amer. J. Path.*, 56, 305 (1969).
10. Kupor, L. R., Mullins, J. D., McPhaul, J. J. Jr.: Immunopathologic findings in idiopathic renal haematuria. *Arch. Int. Med.*, 135, 1204 (1975).

11. Lagrue, G., Hirbec, G., Fournel, M., Intrator, L.: Glomérulonéphrite mésangiale à dépôts d'IgA: Étude des immunoglobulines sériques. *J. Urol. Néphrol.* (Paris), 4, 385 (1974).
12. Lagrue, G., Hirbec, G., Fournel, M., Intrator, L.: Serum immunoglobulins in mesangial IgA deposit glomerulonephritis. *Kidney Int.*, 6, 254 (1974).
13. Lange, K., Wasserman, E., Slobody, L. B.: The significance of serum complement levels for the diagnosis and prognosis of acute and subacute glomerulonephritis and lupus erythematosus disseminatus. *Ann. Int. Med.*, 53, 636 (1960).
14. Lowance, D. C., Mullins, J. D., McPhaul, J. J. Jr.: Immunoglobulin A (IgA) associated glomerulonephritis. *Kidney Int.*, 3, 167 (1973).
15. Maintz, J., Elema, J. D., Henningsen, B.: Eine Sonderform der chronischen Glomerulonephritis: IgG—IgA Nephropathie. *Dtsch. Med. Wschr.*, 97, 1527 (1972).
16. Mancini, G., Carbonara, A. O., Heremans, J. F.: Immunochemical quantitation of antigens by single radial immunodiffusion. *Immunochemistry*, 2, 235 (1965).
17. Mauer, S. M., Sutherland, D. E. R., Howard, R. J., Fish, A. J., Najarian, J. S., Michael, A. F.: The glomerular mesangium. III. Acute immune mesangial injury. A new model of glomerulonephritis. *J. Exp. Med.*, 137, 553 (1973).
18. McCoy, R. C., Abramowsky, C. R., Tisher, C. C.: IgA nephropathy. *Amer. J. Path.*, 76, 123 (1974).
19. Morel-Maroger, L., Mery, J. P. H., Robert, C. L., Rickett, G.: Glomerulonephritis: morphology, natural history and treatment. Kincaid-Smith, P. (ed.). John Wiley and Sons, New York 1973, p. 301.
20. van de Putte, L. B. A., de la Rivière, G. B., van Breda Vriesman, P. J. C.: Recurrent or persistent haematuria: Sign of mesangial immuno-complex deposition. *New Engl. J. Med.*, 290, 1165 (1974).
21. Sainte-Marie, G.: A paraffin-embedding technique for studies employing immunofluorescence. *J. Histochem. Cytochem.*, 10, 250 (1962).
22. Sissons, J. G. P., Woodrow, D. F., Curtis, J. R., Evans, D. J., Gower, P. E., Sloper, J. C., Peters, D. K.: Isolated glomerulonephritis with mesangial IgA deposits. *Brit. Med. J.*, 3, 611 (1975).
23. Süle, T.: A quantitativ vizeletüledék vizsgálat egyszerűsítése (Simplified quantitation of urinary sediment). *Orv. Hetil.* 111, 152 (1970).
24. Thoenes, G. H.: The immunohistology of glomerulonephritis. Distinctive marks and variability. Current topics in pathology. *Glomerulonephritis*, 61, 75 (1976).
25. Tourville, D. R., Adler, R. H., Bienenstock, J., Tomasi, T. B.: The human secretory immunoglobulin system: immunohistological localisation of gamma A, secretory "piece" and lactoferritin in normal human tissues. *J. Exp. Med.*, 129, 411 (1969).
26. Urizar, R. E., Michael, A., Sisson, S., Vernier, R. L.: Anaphylactoid purpura. II. Immunofluorescent and electron microscopic studies of the glomerular lesions. *Lab. Invest.*, 19, 437 (1968).
27. Vernier, R. L., Resnick, J. S., Mauer, S. M.: Recurrent haematuria and focal glomerulonephritis. *Kidney Int.*, 7, 224 (1975).
28. Zimmermann, S. W., Burkholder, P. M.: Immunoglobulin A nephropathy. *Arch. Int. Med.*, 135, 1217 (1975).

Reviews of the Hungarian Academy of Sciences are obtainable
at the following addresses:

ALBANIA

Drejtorija Qëndrone e Përhapjes
dhe Propagandimit të Librit
Kruja Konferenca e Pëzes
Tirana

AUSTRALIA

A. Keesing
Box 4886, GPO
Sydney

AUSTRIA

Globus
Höchstädtplatz 3
A-1200 Wien XX

BELGIUM

Office International de Librairie
30, Avenue Marnix
Bruxelles 5
Du Monde Entier
5, Place St. Jean
Bruxelles

BULGARIA

Hemus
11 pl Slaveikov
Sofia

CANADA

Pannonia Books
2, Spadina Road
Toronto 4, Ont.

CHINA

Waiwen Shudian
Peking
P. O. B. 88

CZECHOSLOVAKIA

Artia
Ve Směšákách 30
Praha 2
Poštovní Novinová Služba
Dovoz tisku
Vinohradská 46
Praha 2
Maďarská Kultura
Praha 2
Václavské nám. 2
Praha 1
Slovart A. G.
Gorkého
Bratislava

DENMARK

Ejnar Munksgaard
Nørregade 6
Copenhagen

FINLAND

Akateminen Kirjakauppa
Keskuskatu 2
Helsinki

FRANCE

Office International de Documentation
et Librairie
48, rue Gay-Lussac
Paris 5

GERMAN DEMOCRATIC REPUBLIC

Deutscher Buch-Export und Import
Leninstraße 16
Leipzig 701
Zulassungsvertriebsamt
Friedrichstraße 3-4
1004 Berlin

GERMAN FEDERAL REPUBLIC

Kunst und Wissen
Erich Bieber
Postfach 46
7 Stuttgart 5.

GREAT BRITAIN

Blackwell's Periodicals
Oxford House
Magdalen Street
Oxford
Collet's Subscription Import
Department
Denington Estate
Wellingsborough, Northants.
Robert Maxwell and Co. Ltd.
4-5 Fitzroy Square
London W.

HOLLAND

Swetz and Zeitlinger
Keizersgracht 471-478
Amsterdam
Martinus Nijhoff
Lange Voorhout 9
The Hague

INDIA

Hind Book House
66 Babar Road
New Delhi 1

ITALY

Santo Vassia
Via M. Macchi 71
Milano
Libreria Commissionaria Sansoni
Via, La Marmora 45
Firenze

JAPAN

Kinokuniya Book-Store Co. Ltd.
826 Tsunohazu 1-chome
Shinjuku-ku
Tokyo
Maruzen and Co. Ltd.
P. O. Box 605
Tokyo-Central

KOREA

Chulpenmul
Phenjan

NORWAY

Tanum-Cammermeyer
Karl Johansgt 41-43
Oslo 1

POLAND

RUCH
ul. Wronia 23
Warszawa

ROUMANIA

Carlitex
Str. Aristide Briand 14-18
Bucuresti

SOVIET UNION

Mezhunarodnaya Kniga
Moscow G-200

SWEDEN

Almqvist and Wiksell
Gamla Brogatan 26
S-101 20 Stockholm

USA

F. W. Faxon Co. Inc.
15 Southwest Park
Westwood, Mass. 02090
Stechert Hafner Inc.
31, East 10th Street
New York, N. Y. 10003

VIETNAM

Xunhasaba
19, Tran Quoc Toan
Hanoi

YUGOSLAVIA

Forum
Vojvode Mišića broi 1
Novi Sad
Jugoslavenska Knjiga
Terazije 27
Beograd